School of Anatomy and Human Biology - The University of Western Australia

Blue Histology - Lymphoid Tissues I

Topics	Lab Guides and Images
Lymphoid Tissues	
Thymus	Thymus, young - H&E
Involution of the Thymus	Thymus, adult - H&E
Lymph Nodes	Lymph Node - H&E, carbon injected

Additional Resources

These links will open a new browser window.

Large Images

Search the Large Images page with the keywords: lymphoid tissue, thymus, lymph node, cortex, paracortex, medulla, lymph follicle, germinal center, subcapsular sinus, medullary sinus, medullary cords, high-endothelial venules or lymphocytes.

VScope

Magnification & Stage Simulation: thymus, H&E

Self Assessment

Choose subject area "lymphoid organs and tissues" on the Quiz page. This subject area covers the Lymphoid Tissue I & II pages of this site.

LYMPHOID TISSUES

Lymphoid (or lymphatic) tissues, which mainly consist of dense accumulations of lymphocytes, are widely distributed in the body. Lymphoid tissues are typically located at sites that provide a possible route of entry of pathogens and/or sites that are liable to infections. Epithelia delimit all other tissues from the "outside world" and it is not surprising that lymphoid tissues are often found near them. Such lymphoid tissues are grouped together as *epithelium-associated lymphoid tissues*. Depending on their precise location these lymphoid tissues may be referred to as e.g. *mucosa-associated lymphoid tissue (MALT)* or bronchus-associated lymphoid tissue (BALT). The tonsils or Peyer's patches are examples of mucosa-associated lymphoid tissues. Lymphoid tissues represent the sites of proliferation and differentiation of lymphocytes.

Lymphoid organs may be defined as anatomical "entities" which consists chiefly of lymphoid tissues. The thymus is a primary lymphoid organ in that it supplies other lymphoid organs and tissues with T-

lymphocytes. Inserted into the blood and lymph vascular system, the spleen and lymph nodes (secondary lymphoid organs) monitor the internal environment of the body.

Thymus

The thymus is situated in the upper parts of the thorax, behind the sternum and the upper four costal cartilages, in the anterior and superior mediastina. The size of the thymus changes in the course of life. It weighs about 10-15 g at birth and reaches its top weight (about 30-40 g) at puberty. After puberty a progressive involution (see below) occurs, which leaves a middle-aged person with a thymus weighing about 10 g. The thymus consists of a right and left lobe which are joined by connective tissue.

The thymus is enclosed by a *thin connective tissue capsule* from which numerous septa extend into the thymus subdividing the two lobes into numerous lobules (about 0.5 -2 mm in diameter). Blood vessels enter and leave the thymus via the connective tissue septa. Each lobulus is divided into a darker peripheral zone, the *cortex*, and a lighter, central zone, the *medulla*. Medullary tissue is continuous from lobule to lobule throughout each lobe.

Reticular cells and macrophages are present in addition to the lymphocytes, which are the dominant cell type within the lobules.

Reticular cells

are quite abundant. Their cytoplasm is eosinophilic, and their large, ovoid and light nuclei may contain one or two nucleoli. The cells are branched, and their slender processes are connected with the processes of other reticular cells to form a cellular reticulum (or cellular network). This cellular network (reticular fibres are scant in the thymus) provides support for other cells of the thymus.

Reticular cells sheathe the cortical capillaries; they form an epitheloid layer which delimits the cortical tissue from the connective tissue and secrete substances (hormones and other factors) important for thymic function. Thereby they create and maintain the microenvironment necessary for the development of T-lymphocytes in the cortex. Their functions thus go beyond those of "typical" reticular cells and, to reflect this, they are also referred to as thymic epitheliocytes.

Macrophages

occur in both cortex and medulla. They are difficult to distinguish from the reticular cells in H&E stained sections.

Lymphocytes

are present in both cortex and medulla, but are more numerous (denser) in the cortex. Their sizes are variable (5 - 15 µm) in the cortex but generally small in the medulla. The vast majority of them will be developing T-lymphocytes. They are also called thymic lymphocytes or thymocytes.

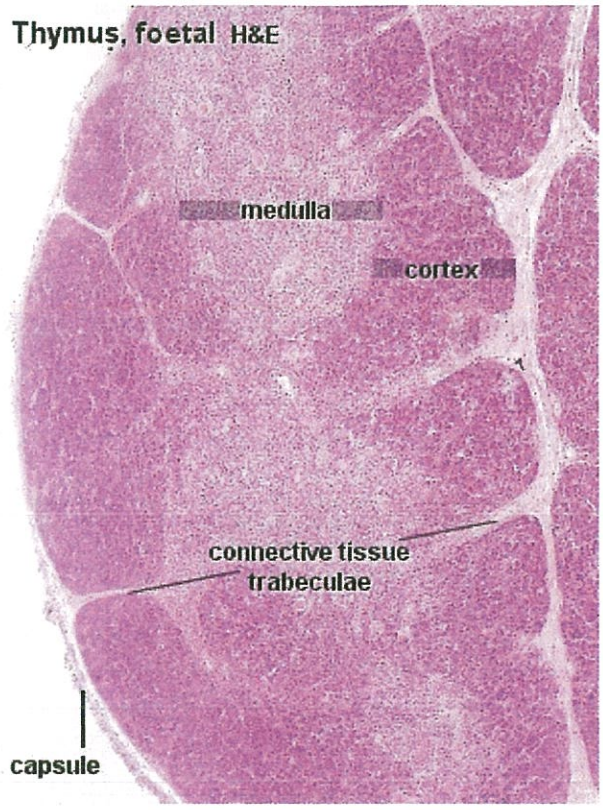

Thymus, foetal human - H&E

Identify the connective tissue capsule and septa, a lobule and its cortex and medulla at low magnification. Identify lymphocytes and thymic corpuscles. They look pretty much like a sliced (very, very small) onion. Take a close look at the medulla and try to find some cells which contain large and light nuclei. They will be either macrophages or reticular cells.

Sketch part of the thymus at low magnification. Identify medulla and cortex. Draw a segment of a lobule at high magnification and identify lymphocytes and nuclei of reticular cells/macrophages and, if possible a Hassall corpuscle.

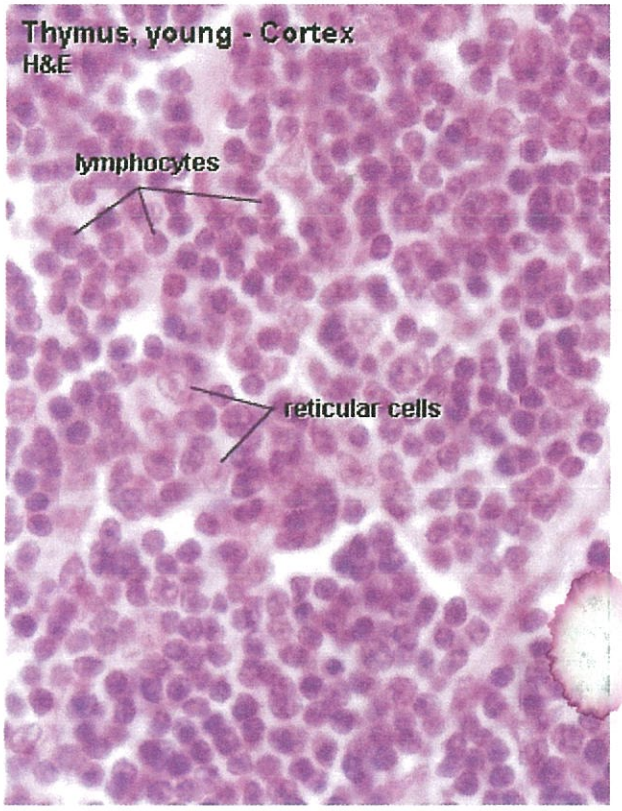

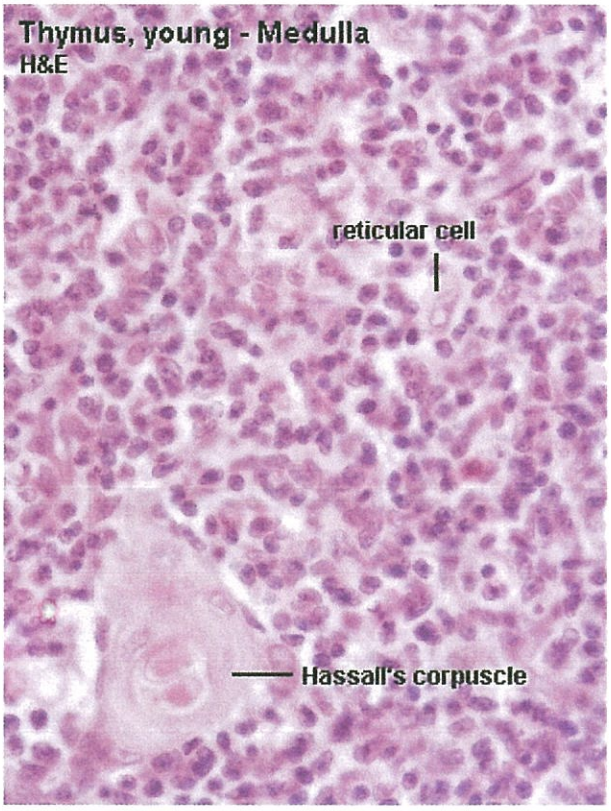

Function of the Thymus

The thymus is necessary for the development of the recirculating pool of small, long-lived (in humans many years) lymphocytes, the *T-lymphocytes*. These cells are mainly responsible for the *cell-mediated part of an immune response*. Stem cells invade the cortical regions of the thymus, where they divide to form lymphocytes. Only a small fraction (estimates range from 10-30%) of the cells generated in the cortex leave the thymus. They migrate via the medulla into the blood stream to populate the T-lymphocyte areas of other lymphoid tissues and organs. Cells which do not express the necessary receptors to recognize antigens presented to them or which react incorrectly towards "self-antigens" die and are removed by cortical macrophages.
Since the function of the thymus is to produce lymphocytes for the other lymphoid tissues it is a *primary lymphoid organ*.

Involution of the thymus

After puberty much of the parenchyma of the thymus, in particular cortical lymphoid tissue, is replaced by adipose tissue. The process, which is called *involution*, initially proceeds rapidly but slows down in adulthood. Involution is under the control of steroid hormones (both sexual hormones and stress hormones). *Although most pronounced in the thymus, involution is a common feature of all lymphoid tissues*.

Another age-related phenomenon is the increase in size of the *thymic (or Hassall's) corpuscles*. Thymic corpuscles are rounded eosinophilic structures, which consist of concentrically arranged, flattened cells. Thymic corpuscles are likely to be formed by reticular cells. Similar structures occur also in the tonsils. The size of these structures varies from 20 µm to more than 100 µm in diameter. Thymic corpuscles may calcify, and their core may "dissolve" leading to the formation of a cyst.

Thymus, adult human - H&E
Draw a part of the tissue, which illustrates the presence of adipose tissue, and the decrease in the amount of cortical and medullary thymic tissue. Include thymic corpuscles in your drawing if you can find them.

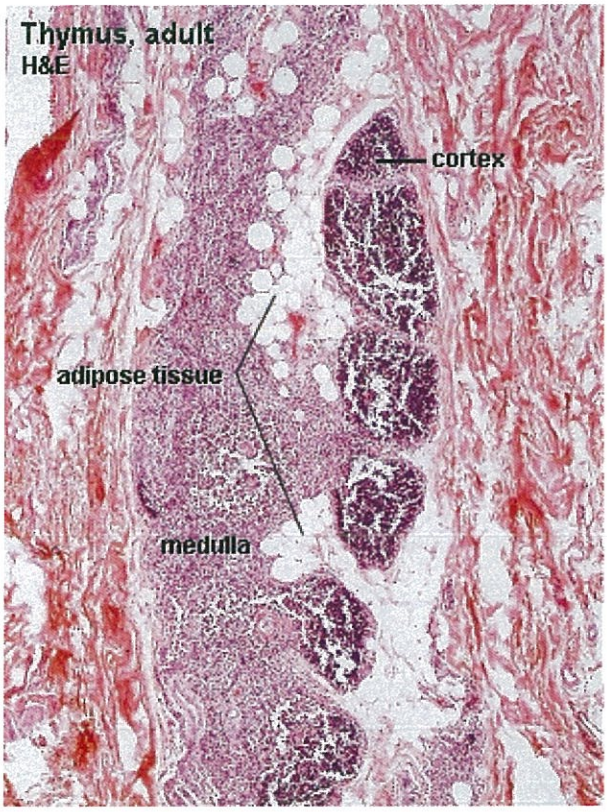

Lymph Nodes

Lymph nodes are small, flattened, oval or bean shaped organs, which are situated in the course of the collecting lymph vessels. Their size is variable (from a few mm to more than 2 cm). The capsule and trabeculae of lymph nodes are formed by connective tissue. *Afferent lymph vessels penetrate the capsule* and empty into the subcapsular space. The lymph continues thereafter through cortical and medullary sinuses towards the *efferent lymph vessels*, which *emerge from the hilus of the lymph node*. The walls of the sinuses can be traversed freely by all components of the lymph, which allows lymphocytes to enter/leave the lymphoid tissue (as part of their constant circulation) or to get in contact with antigens/antigen-presenting cells that may arrive with the lymph.

In lymph nodes we find B- and T-lymphocytes, macrophages and reticular cells.

Reticular cells

> (and reticular fibres) form a delicate network between the capsule and trabeculae. Only their large and light nuclei are easily visible in the microscope. The cytoplasm of reticular cells is only weakly eosinophilic. Lymphocytes and macrophages are housed in the network of

reticular cells and the reticular fibres formed by them. The processes of reticular cells and reticular fibres extend into and criss-cross within the sinuses.

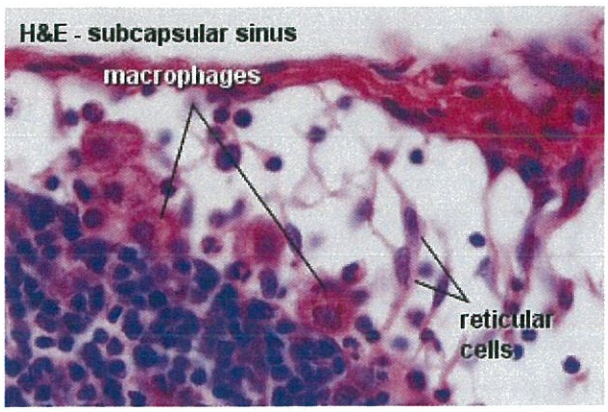

Lymphocytes

which are located in the outer cortex of the lymph node are likely to represent *B-lymphocytes*. They are organised into spherical masses - *lymphoid nodules or follicles*. Sites within the cortex at which B-lymphocytes have been stimulated to proliferate (by contact with an antigen) appear lighter than the surrounding tissue and allow you to identify the centres of lymphoid nodules. The lighter stained parts of the nodules are called *germinal centres*. Mature B-lymphocytes (plasma cells) are located in cord-like extensions of the lymphoid tissue into the medulla, the *medullary cords*. *T-lymphocytes* are located in the more diffuse tissue between the nodules and in the *paracortex*, i.e. the deep part of the cortex.

Macrophages

are found scattered within the lymphoid tissue. In many preparations they are difficult to distinguish from the reticular cells, but if an H&E stain turns out nice, macrophages can be distinguished from the reticular cells in the sinus system of the lymph node.

Blood Vessels

Blood vessels enter the lymph nodes through the hilus and travel initially in the connective tissue trabeculae that extend from the hilus into the parenchyma of the lymph node. They continue in the medullary cords towards the cortex and give off capillaries to the surrounding tissue as they do so. *High-endothelial venules* (or *postcapillary venules*) in the deep cortex have a characteristic low cuboidal epithelium - quite unlike the squamous epithelium that we usually would expect to see. Lymphocytes, which reach the lymph node via the blood stream, may migrate through this epithelium as part of their recirculation. Larger venules accompany the arteriolar branches as they leave the lymph nodes.

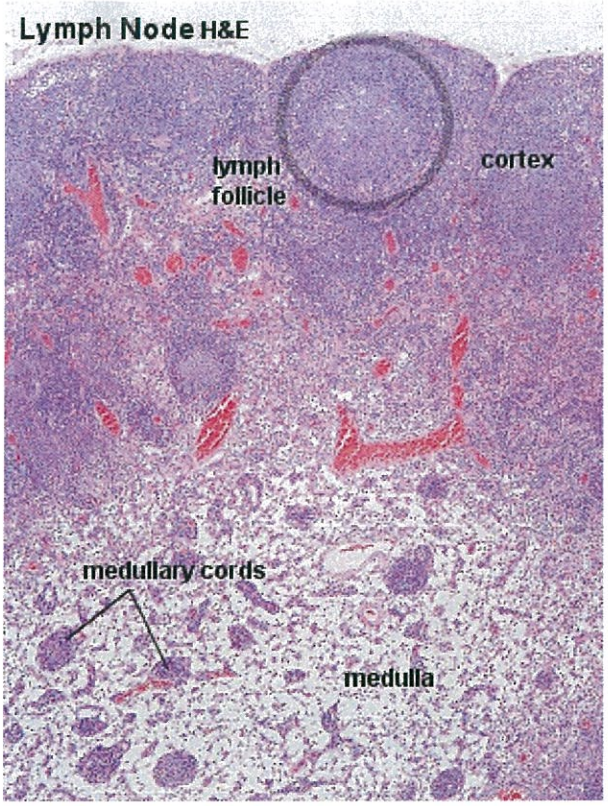

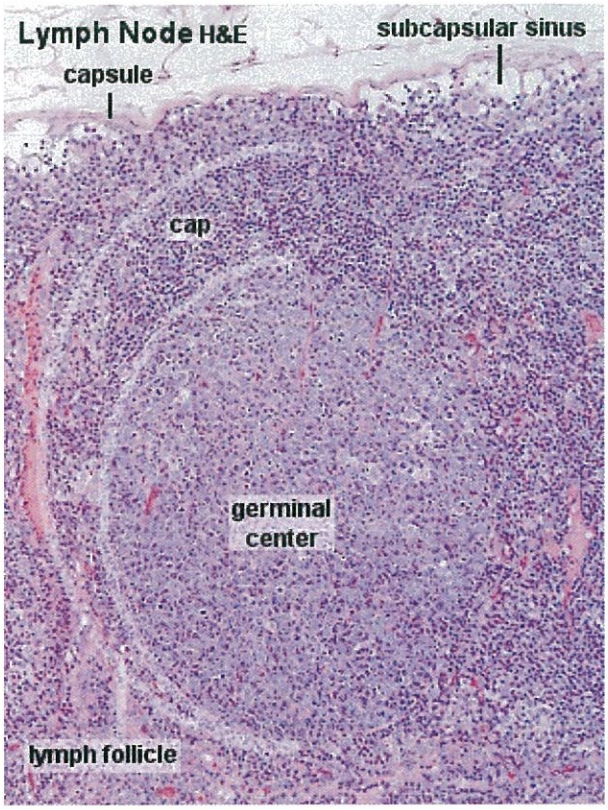

Lymph node, rabbit - H&E

The subcapsular and cortical sinus system was hardly (if at all) visible in the slides I looked at. Identify the connective tissue capsule and trabeculae, cortex and medulla of the lymph node, lymph nodules with germinal centres, medullary cords and postcapillary venules.

Draw a section of the lymph node in which you can see the capsule and a nodule. Include, if possible, a postcapillary venule at high magnification.

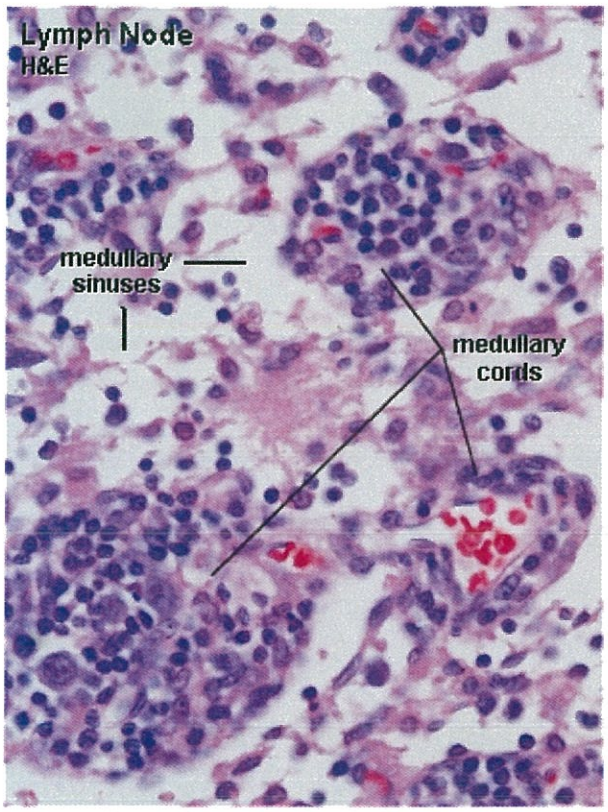

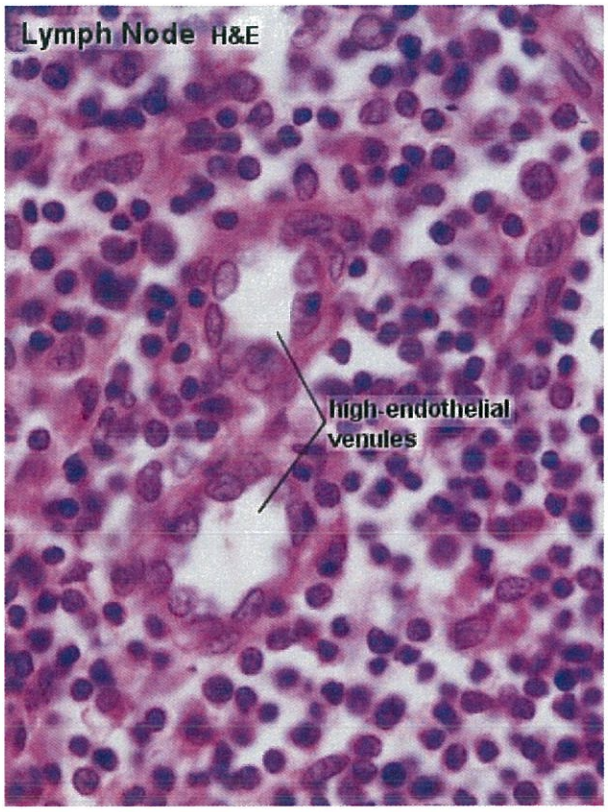

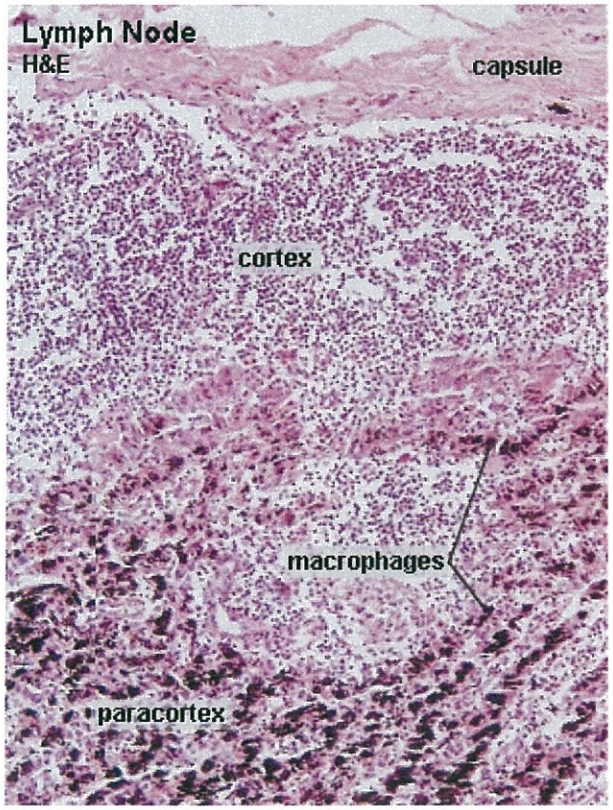

Lymph node - H&E, carbon injected
This slide illustrates the distribution of macrophages in lymph nodes - take a quick look at them. Note that most of them are located in the paracortex and medulla.

---

page content and construction: Lutz Slomianka
last updated: 1/10/06

School of Anatomy and Human Biology - The University of Western Australia

Blue Histology - Lymphoid Tissues II

Topics

Lab Guides and Images

Additional Resources

These links will open a new browser window.

Large Images

Search the Large Images page with the keywords: lymphoid tissue, spleen, tonsil, GALT, gut-associated lymphoid tissue, Peyer's patch, red pulp, white pulp, central artery, splenic sinuses, splenic cords, tonsilar crypt or reticulated stratified squamous epithelium.

VScope

Magnification & Stage Simulation: spleen, human, H&E

Focus & Stage Simulation: spleen, reticular connective tissue, reticulin

Self Assessment

Choose subject area "lymphoid organs and tissues" on the Quiz page. This subject area covers the Lymphoid Tissue I & II pages of this site.

Spleen

The spleen is, like the lymph nodes, a *discriminatory filter*. Unlike the lymph nodes, the spleen is inserted into the blood stream. The spleen clears the blood of aged blood cells and foreign particles and is the *site of immune reactions to blood-borne antigens*. The spleen is not essential to life in adult individuals. Other organs can take over its functions if the spleen is removed.

The spleen is surrounded by a *capsule* of dense connective tissue from which branched trabecula extend into the parenchyma of the spleen (sounds familiar). The parenchyma of the spleen is termed the *pulp* of the spleen. Most of the pulp of a fresh, unfixed spleen is a soft, dark red mass, the *red pulp*. It consists of large, irregular, thin-walled blood vessels, the *splenic sinusoids*, interposed between sheets and strands

of reticular connective tissue, the *splenic cords* (of Billroth). Within the red pulp small, oval or rounded greyish white areas, the *white pulp*, is formed by lymphoid tissue.

Branches of the splenic artery (Where does it enter the spleen?) divides into *trabecular arteries* (Where are they found?), which enter the white pulp, where they are called *central arteries*. Branches of the central artery almost all divide into smaller vessels in the marginal zone, i.e. the border between the red and white pulp. Fine branches of the central artery - *penicillar arteries* (cuboidal epithelium) - branch again to form arterial capillaries, which, as they exit the white pulp, are surrounded by a sheath of phagocytotic cells and reticular fibres. They are now called *sheathed arteries*. From here, the blood enters the red pulp. Sheathed arteries may empty the blood which they carry directly into the splenic sinusoids (*closed circulation*, about 90% in cats) or into the reticular connective tissue of the splenic cords (*open circulation*). Macrophages are, in addition to reticular cell, the main resident cell population of the splenic cords.

Blood cells which are emptied into the splenic cords re-enter the blood vessels through the endothelium of the sinusoids. The endothelial cells are elongated (in cross section they may appear cuboidal) and oriented along the long axis of the sinusoids. The endothelium of the sinusoids has no junctional complexes and its basement membrane is incomplete (forming narrow circular bands around the endothelial cells with large intervening fenestrations). Macrophages ingest aged erythrocytes, platelets and other particulate matter as they pass through the splenic cords.

The composition of the plasma membrane of erythrocytes changes as the cell ages. It is thought that these changes eventually expose erythrocyte senescence antigens, which bind blood-borne antibodies and thus tag the erythrocyte for removal by macrophages. Erythrocyte removal is also one function of the resident macrophages of the liver, although splenic macrophages take care of most of the job.

The sinusoids continue into the veins of the pulp, which empty into thin-walled *trabecular veins*, which eventually coalesce to form the splenic vein.

The white pulp surrounds the central arteries as a *periarterial lymphoid sheath (PALS)*. Lymphocytes of the PALS are likely to be T-lymphocytes. In addition, we see macrophages and plasma cells in the PALS. Lymph nodules, formed by B-lymphocytes, are present along the course of the central arteries. The central arteries are typically located in the periphery of the nodule.

Spleen, human - H&E

Find a place close to the capsule where you can identify trabeculae, white pulp (possibly a nodule with a peripherally placed central artery), and red pulp. Good penicillar and sheathed arteries are very hard to identify - do not despair if you (or the demonstrator) cannot find them. As usual, it is easiest to identify macrophages by accumulations of particulate matter in their cytoplasm, which often will represent disintegrating erythrocytes.

Sketch your observations (the 10x objective should be fine).

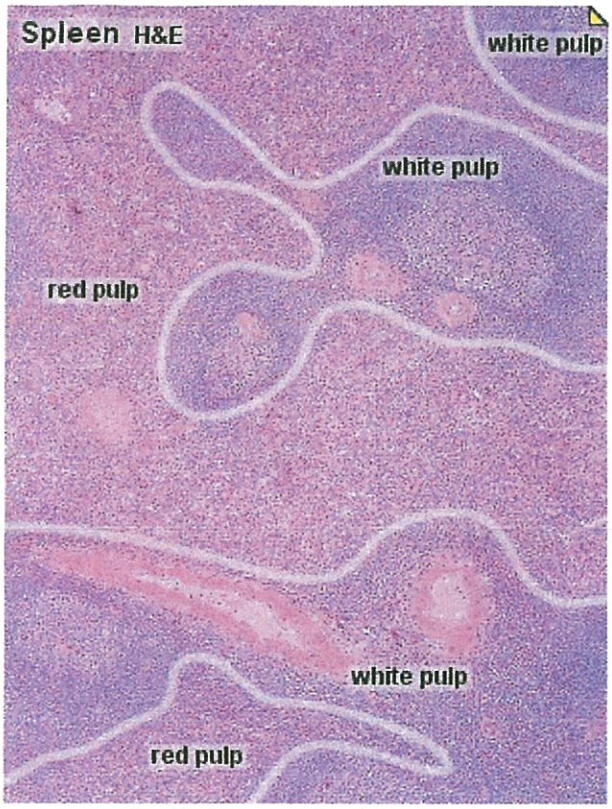

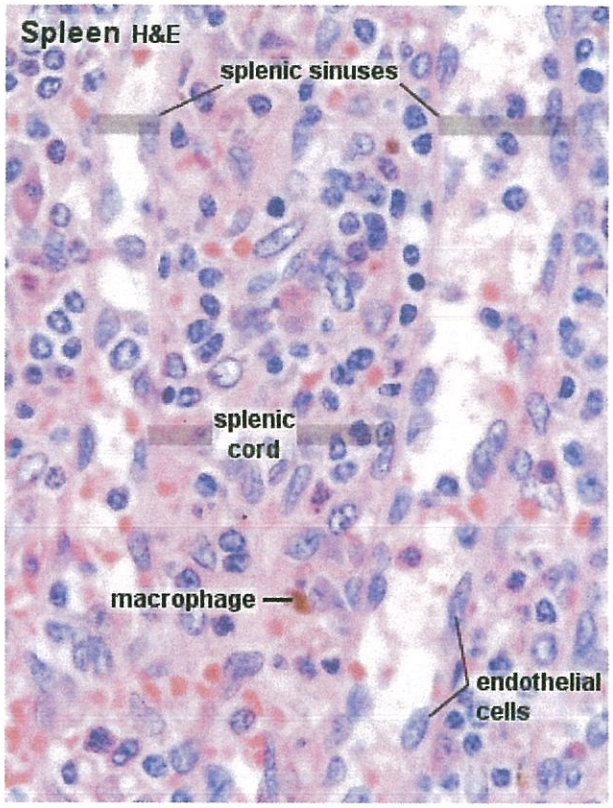

Spleen, cat - reticulin

This slide illustrates the distribution of reticular fibres in the spleen. They often appear coarser in the red pulp, where they have a distinct, stranded organisation. The reticular fibres of the white pulp appear somewhat finer and, at times, they are arranged as concentric rings. The peripheral localisation of the central arteries in nodules is quite distinct. Occasionally you may see small rings of reticular fibres in (or close to) the periphery of the white pulp. These rings are likely to represent the reticular fibres surrounding sheathed arteries.

Sketch your observations (the 10x objective is sufficient).

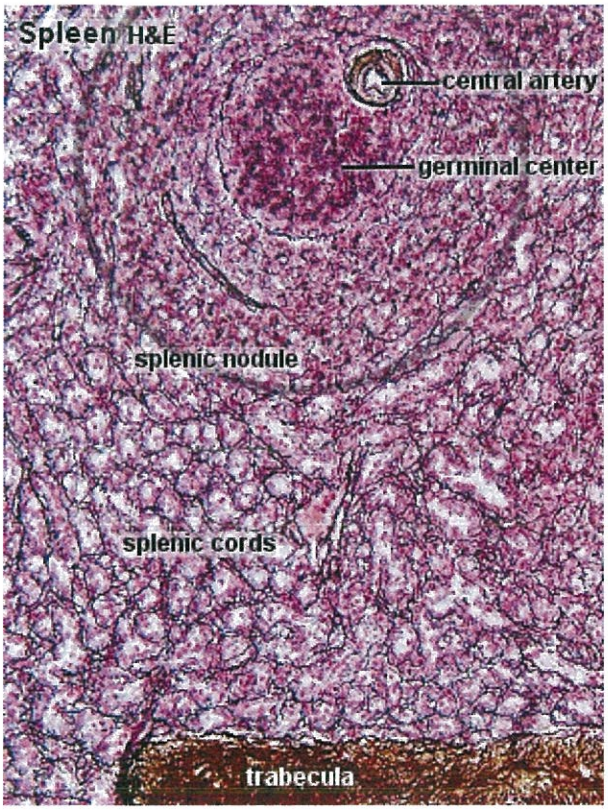

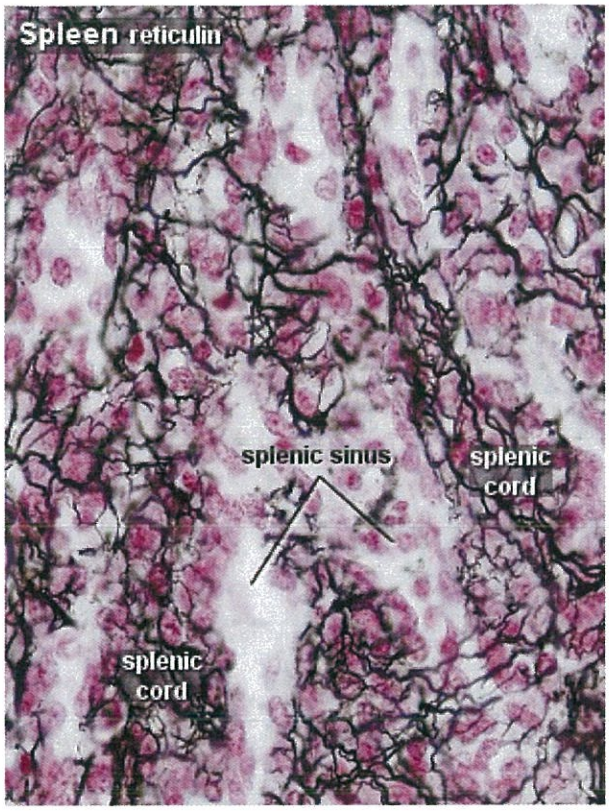

Mucosa-Associated Lymphoid Tissue

The mucosal lining of the alimentary canal and airways is in many ways specialised to facilitate the exchange of substances between the external environment and the body. Unfortunately, these specialisation do not just apply e.g. to components of the digested food but also pathogens. This is combined with excellent living conditions for bacteria in parts of the alimentary canal - in particular the ileum and the colon. Lymphoid tissue located beneath the mucosal epithelia, *mucosa-associated lymphoid tissue* (MALT), protects the body against pathogens that may enter the body via the mucosa. The importance of this task is reflected in the mass of the MALT, which corresponds to the combined mass of the other lymphoid organs and tissues.

The task that the immune cells of the MALT have to accomplish is different from that of other parts of the immune system. We do need a defense against pathogens, but it would not be a good idea to mount an immune response against components of the food. Immune cell activation therefore differs between the MALT and other lymphoid tissues.

This difference is mediated by different receptors expressed by immune cells of the MALT and by different substances which they release upon contact with an antigen. Because of their specific functions, immune cells of the MALT do not mingle with other immune cells. Epithelial cells of the vessels supplying the MALT express specific receptor which are recognized by MALT immune cells and allow their homing to the MALT during recirculation. Lastly, MALT plasma cells produce a secretable form of antibodies, immunoglobulin type A dimers, which can be taken up by epithelial cells and then released onto the

epithelial surface.

Specialisation of MALT immune cells occur at the molecular level. In routine histological preparations, immune cells of the MALT look pretty much like immune cells of other lymphoid tissues.

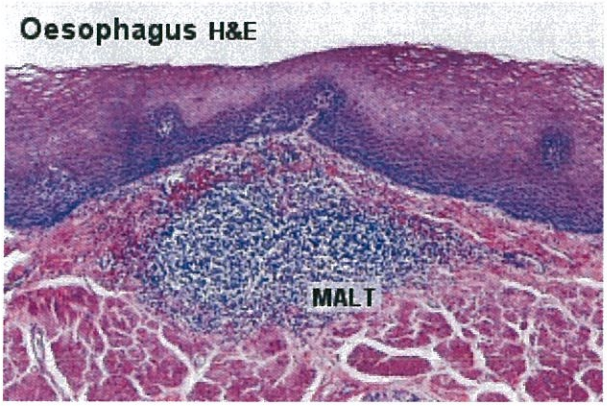

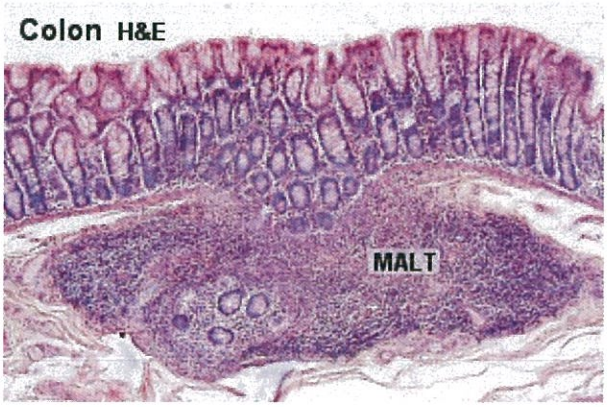

Often MALT consists of small accumulations of lymphoid cells or one to a few lymph follicles beneath the epithelium and possibly extending into the submucosa. The *tonsils* and *Peyer's patches* are large accumulations of lymphoid tissue with associated specialisations of the epithelium.

Tonsils

The tonsils are *accumulations of lymphoid tissue surrounding the openings of the digestive and respiratory tracts*. The tonsils and smaller accumulations of lymphoid tissue, which may be found between them, are also called Waldeyer's ring.

Depending on their localisation we distinguish between

- *palatine tonsils* (THE tonsils), which are located in the lateral wall of the oropharynx and covered by a stratified squamous epithelium,
- *lingual tonsils* which are situated in the lamina propria at the root of the tongue and also covered by a stratified squamous epithelium, and
- *pharyngeal tonsils* (also called nasopharyngeal tonsils or adenoids) which are located in the upper posterior part of the throat (nasopharynx) and covered by a pseudostratified ciliated epithelium with goblet cells.

The *tonsils do not have afferent lymph vessels*. Efferent lymph vessels are present. Exposure to antigens relies on the contact of antigens with cells of the immune system across the epithelium which covers the tonsils. The epithelium of the palatine and lingual tonsils forms deep crypts into the lymphoid tissue,

and the resulting increase of the surface area is one way to facilitate the contact of antigens with the immune cells. In addition, the epithelium may specialise in places to form an open meshwork of cells with an incomplete basal lamina (a *reticulated epithelium*) which allows the infiltration of the epithelium by lymphocytes and macrophages.
Tonsillar lymphoid nodules consist mainly of B-lymphocytes. Other areas are occupied by T-lymphocytes, activated B-lymphocytes and other cells of the immune system.

The tonsils share some histological features with lymph nodes:

1. cells in the tonsils are supported by a fine network of reticular fibres and
2. high-endothelial (postcapillary ~) venules function in the "homing" of circulating lymphocytes - this is actually a shared feature of all lymphoid tissues and organs.

The palatine tonsils are surrounded by a thick hemicapsule of connective tissue, which delimits them from the pharyngeal muscle and facilitates their removal in tonsillitis.

Tonsil, human - H&E
Identify the surface epithelium covering the lymphoid tissue of the tonsils, lymph nodules and tonsillar crypts. Have a look at the epithelium both inside and outside the crypts. Outside the crypts, the epithelium will typically look like ordinary stratified squamous epithelium. Inside the crypts, where cells of the immune system often invade the epithelium, it will be difficult to find the boundary between epithelium and lymphoid tissue. Tissue preservation is not that great, but with a little bit of patience you should be able to find high-endothelial venules in the lymphoid tissue.
Sketch the organisation of the tissue at low magnification.

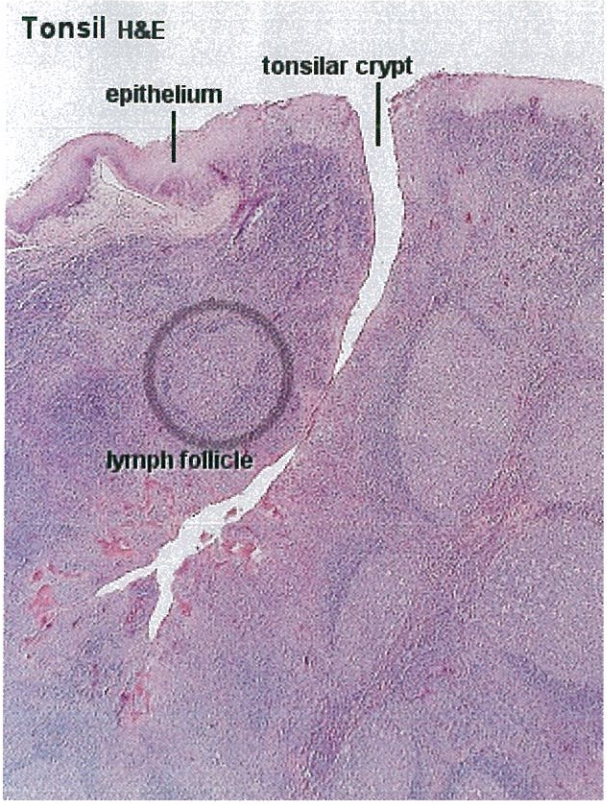

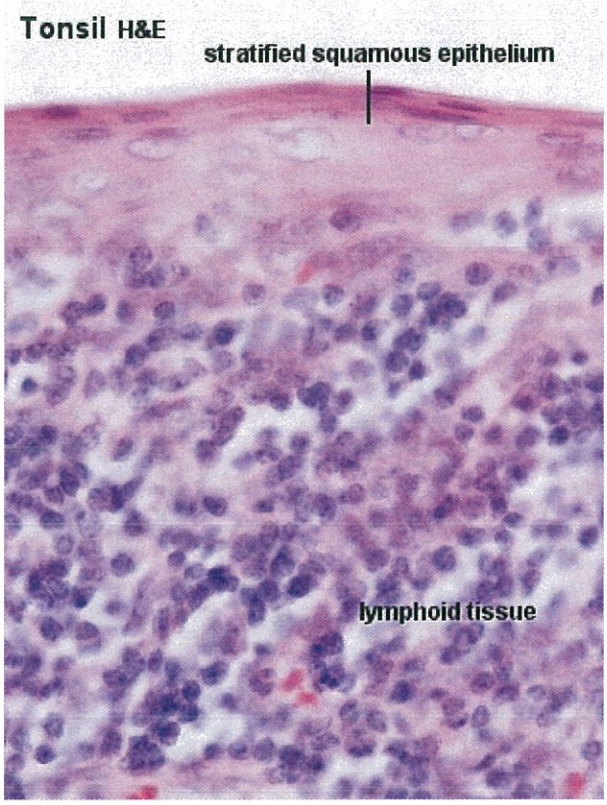

Gut-Associated Lymphoid Tissue - GALT

Small accumulations of lymphocytes or solitary lymph follicles are found scattered in beneath the epithelium throughout the gastrointestinal tract. However, the most prominent accumulations occur in the ileum and appendix in the form of Peyer's patches. In the ileum, they form dome-shaped protrusions into the lumen. Beneath the epithelial lining of the domes, Peyer's patches extend from the lamina propria to the submucosa. Within Peyer's patches, lymph follicles with germinal centers are typically located deep in the submucosa.

The epithelium in contact with the lymphoid tissue is specialised to facilitate the contact of antigens with cells of the immune system. The epithelium appears columnar and contains cells with deeply invaginated basal surfaces - *microfold cells or M-cells*. Immune system cells can enter these invaginations (intraepithelial pockets) where they are exposed to materials which have been endocytosed by the epithelial cells and then released into the invaginations. Goblet cells are rare or absent in the epithelium which covers the domes.

Suitable Slides

slides of appendix, ileum or Peyer's patches - **H&E**

Slides of the appendix and ileum may be useful is there is no specially prepared slide of Peyer's patches. Extensive

areas of lymphoid tissue are alway present in the appendix, but domes and specialised sections of epithelium may not. If you have a slide of the ileum hold it against the light and see if parts of the wall look darker than the rest. These parts are likely to contain lymphoid tissue and may show domes and/or specialised sections of epithelium.

Peyer's Patch, Ileum - H&E

If you hold the sections against a light surface the areas which are occupied by the lymphoid tissue should be readily visible - in H&E stained sections they appear darker than the remaining tissue. Look at these areas under the microscope. Identify the domes and their epithelial covering. The epithelium will be lower than the epithelium covering the villi and goblet cells are rare or absent. See if you can find intraepithelial pockets containing immune cells. Even if no clear pockets are present, some lymphocytes should appear scattered "over" the epithelium. In reality they will be located in the intraepithelial pockets. High-endothelial venules should be present in the lymphoid tissue beneath the domes but may be difficult to find. Next go further towards the submucosa and see if you can find lymph follicles. ***Draw the epithelium covering the domes at high magnification. Include a scetch of the normal intestinal epithelium for comparison. Scetch the appearance of Peyer's patches at low magnification.***

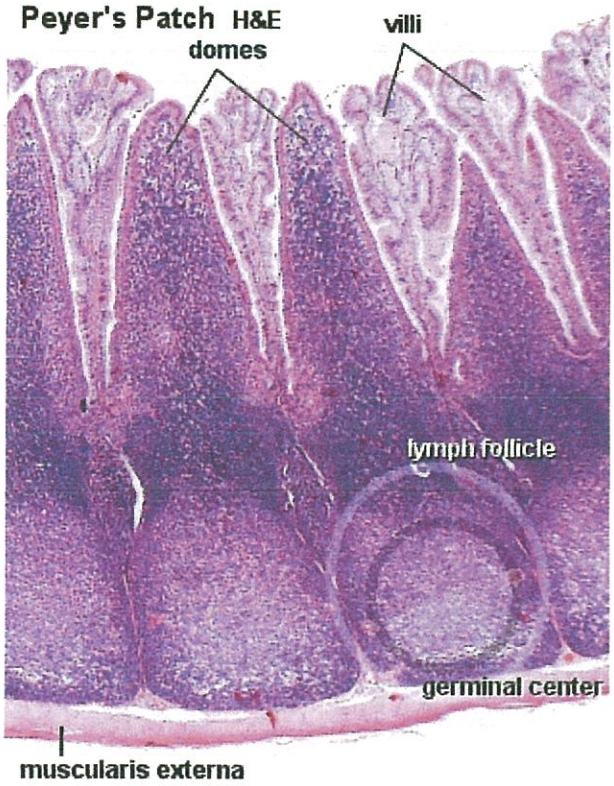

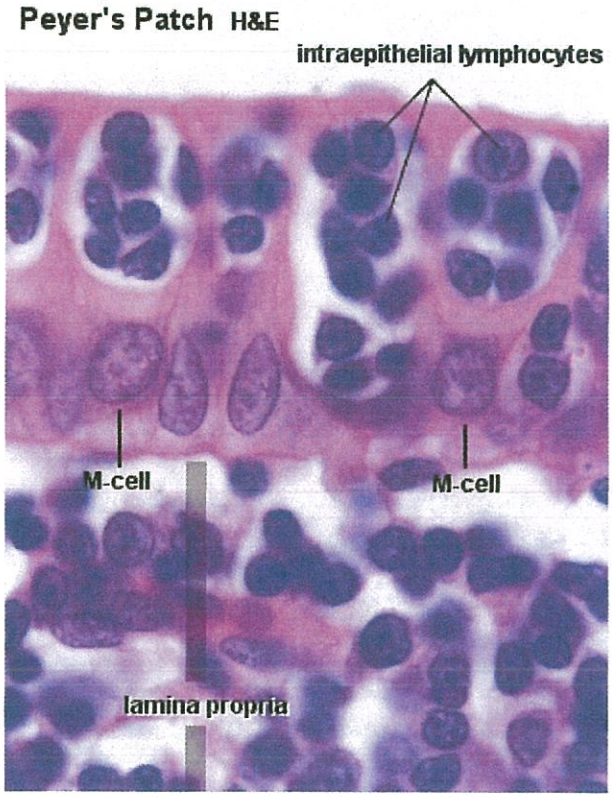

---

page content and construction: Lutz Slomianka
last updated: 1/10/06